

- Vaginal atrophy (VA) is the thinning of the vaginal epithelial lining, caused by a decrease in estrogen levels during menopause. Some of the consequences of VA include increased susceptibility to bacterial infection, vaginal dryness, pain during sexual intercourse (dyspareunia), and vaginal burning or itching. Vaginal atrophy is an important contributor to postmenopausal sexual dysfunction.
- The ovariectomized rat model of vaginal atrophy is a useful model for the understanding of this physiopathological state and the development of new effective therapies.

Pathophysiological features and measurable endpoints

- Decrease in vaginal weight,
- Thinning of the epithelium,
- Decrease in the number of layers in the stratified epithelium
- Severe degeneration in epithelial architecture,
- Smooth muscle atrophy

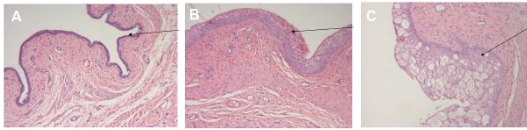


Figure 1: Illustration of vaginal atrophy in ovariectomized female rats not treated (A), receiving hormonal treatment at low dose (B) or high dose (C). (Pelvipharm internal data).

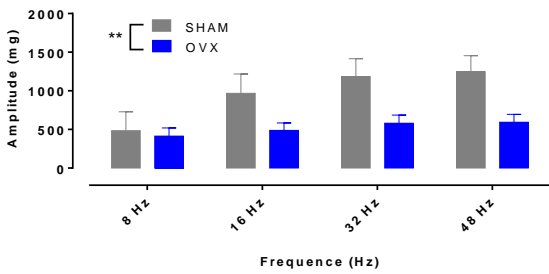


Figure 2: Epithelium thickness reported as percentage increase of ovariectomized rat (OVX) following 6-week intravaginal treatment of OVX rats. Data are mean \pm SEM. **** $p < 0.0001$ Student's t-test. (Pelvipharm internal data).

- Decrease in vaginal smooth muscle contractile and relaxation responses to neuropharmacological / electrical stimulation.

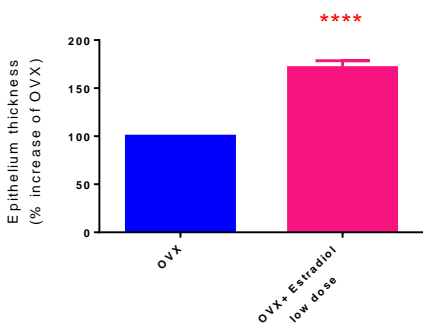


Figure 3: Electrical field stimulation-induced contractions of proximal vaginal strips from sham and ovariectomized (OVX) rats. Data are mean \pm SEM. ** $p < 0.01$, two-way ANOVA. (Pelvipharm internal data).

- Decrease in vaginal blood flow measured by Laser Doppler.

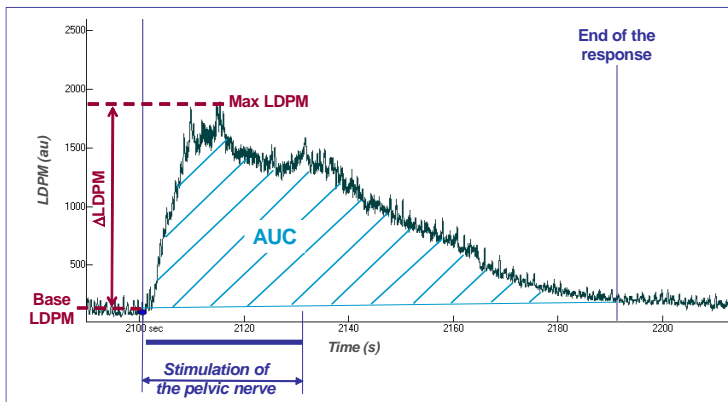


Figure 4: Illustration of the parameters computed for vaginal blood engorgement following electrical stimulation of the pelvic nerve. LDPM, Laser Doppler Perfusion Measurement

- Predominance of leucocytes in the vaginal maturation index (equivalent to predominance of parabasal and intermediate cells reported in women during menopause).

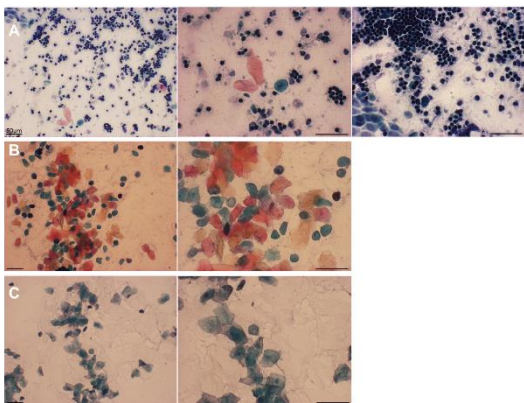
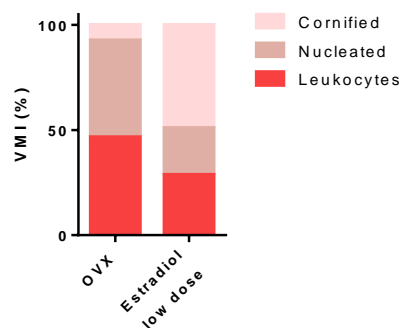
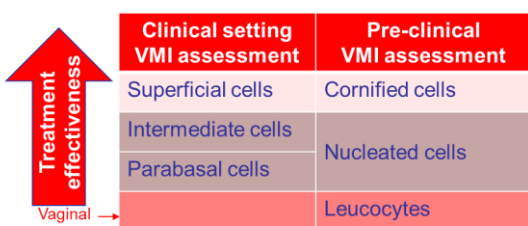


Figure 5: Papanicolaou staining of a representative vaginal smears from (A) ovariectomized rats, (B) non-ovariectomized rats in estrus stage and (C) non-ovariectomized rats in proestrus stage.



VMI=vaginal maturation index is a ratio obtained through performing a random count of 3 major cell types

Related Pelvipharm bibliography:

- Giuliano F *et al.* *Am J Physiol Regul Integr Comp Physiol* (2001):281:R140-149
- Vailati *et al.* *J Sex Med* (2013):1:35-43